

# SpineFAQs

## Lumbar Spondylolisthesis

Normally, the bones of the spine (the vertebrae) stand neatly stacked on top of one another. The ligaments and joints support the spine. Spondylolisthesis alters the alignment of the spine. In this condition, one of the spine bones slips forward over the one below it. As the bone slips forward, the nearby tissues and nerves may become irritated and painful.

### **Why do I have this problem?**

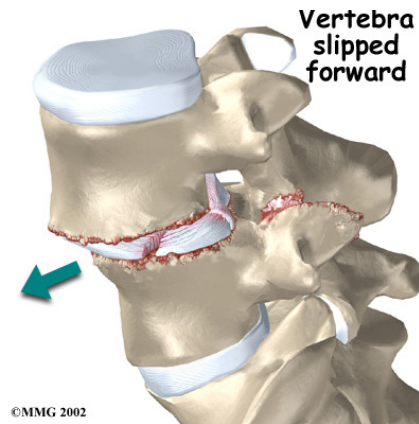
In younger patients (under 20 years old), spondylolisthesis usually involves slippage of the fifth lumbar vertebra over the top of the sacrum. There are several reasons for this. First, the connection of L5 and the sacrum forms an angle that is tilted slightly forward, mainly because the top of the sacrum slopes forward. Second, the slight inward curve of the lumbar spine creates an additional forward tilt where L5 meets the sacrum. Finally, gravity attempts to pull L5 in a forward direction.

The facet joints are small joints that connect the back of the spine together. Normally, the facet joints connecting L5 to the sacrum create a solid buttress to prevent L5 from slipping over the top of the sacrum. However, when problems exist in the disc, facet joints, or bony ring of L5, the buttress becomes ineffective. As a result, the L5 vertebra can slip forward over the top of the sacrum.

A condition called *spondylolysis* can also cause the slippage that happens with spondylolisthesis. Spondylolysis is a defect in the bony ring of the spinal column. It affects the pars interarticularis, mentioned earlier. This defect is most commonly thought to be a stress fracture that happens from repeated strains on the bony ring. Participants in gymnastics and football commonly suffer these strains. Spondylolysis can lead to the spine slippage of spondylolisthesis when a fracture occurs on both sides of the bony ring. The back section of the bony ring separates from the main vertebral body, so the injured vertebra is no longer connected by bone to the one below it. In this situation, the facet joints can't provide their normal support. The vertebra on top is then free to slip forward over the one below.

A traumatic fracture in the bony ring can lead to slippage when the fracture goes completely through both sides of the bony ring. The facet joints are no longer able to provide a buttress, allowing the vertebra with the crack in it to slip forward. This is similar to what happens when spondylolysis (mentioned earlier) occurs on both sides of the bony ring, but in this case it happens all at once.

*Degenerative* changes in the spine (those from wear and tear) can also lead to spondylolisthesis. The spine ages and wears over time, much like hair turns gray. These changes affect the structures that normally support healthy spine alignment. Degeneration in the disc and facet joints of a spinal segment causes the vertebrae to move more than they should. The segment becomes loose, and the added movement takes an additional toll on the structures of the spine. The disc weakens, pressing the facet joints together. Eventually, the support from the facet joints becomes ineffective, and the top vertebra slides forward. Spondylolisthesis from degeneration usually affects people over 40 years old. It mainly involves slippage of L4 over L5.



### **What does the condition feel like?**

An ache in the low back and buttock areas is the most common complaint in patients with spondylolisthesis. Pain is usually worse when bending backward and may be eased by bending the spine forward. Spasm is also common in the low back muscles. The hamstring muscles on the back of the thighs may become tight.

The pain can be from mechanical causes. *Mechanical pain* is caused by wear and tear on the parts of the spine. When the vertebra slips forward, it puts a painful strain on the disc and facet joints.

Slippage can also cause *nerve compression*. Nerve compression is a result of pressure on a nerve. As the spine slips forward, the nerves may be squeezed where they exit the spine. This condition also reduces space in the spinal canal where the vertebra has slipped. This can put extra pressure on the nerve tissues inside the canal. Nerve compression can cause symptoms

where the nerve travels and may include numbness, tingling, slowed reflexes, and muscle weakness in the lower body.

Nerve pressure on the cauda equina, the bundle of nerve roots within the lumbar spinal canal, can affect the nerves that go to the bladder and rectum. The pressure may cause low back pain, pain running down the back of both legs, and numbness or tingling between the legs in the area you would contact if you were seated on a saddle.

### **How do doctors diagnose the problem?**

Diagnosis begins with a complete history and physical exam. I will ask questions about your symptoms and how your problem is affecting your daily activities. I will also want to know what positions or activities make your symptoms worse or better. Next I will examine you by checking your posture and the amount of movement in your low back. Your doctor checks to see which back movements cause pain or other symptoms. Your skin sensation, muscle strength, and reflexes are also tested.

I will usually order X-rays of the low back. The X-rays are taken with your spine in various positions. They can be used to see which vertebra is slipping and how far it has slipped.

If more information is needed, I also order a *magnetic resonance imaging* (MRI) scan. The MRI machine uses magnetic waves rather than X-rays to show the soft tissues of the body. It can help in the diagnosis of spondylolisthesis. It can also provide information about the health of nerves and other soft tissues. I may order *computed tomography* (a CT scan). This is a detailed X-ray that lets me see slices of the body's tissue. If you have nerve problems, I will combine the CT scan with *myelography*. To do this, a special dye is injected into the space around the spinal canal, the *subarachnoid space*. During the CT scan, the dye highlights the spinal nerves. The dye can improve the accuracy of a standard CT scan for diagnosing the health of the nerves.

### **What are the treatments for spondylolisthesis?**

When the vertebra hasn't slipped very far, I start by prescribing non-surgical treatments. In some cases, the patient's condition is simply monitored to see if symptoms improve. Medications may be prescribed to help ease pain and

muscle spasm. I may ask that you rest your back by limiting your activities. This is to help decrease inflammation and calm muscle spasm. You may need to take time away from sports or other strenuous activities to give your back a chance to heal. If you still have symptoms after a period of rest, your doctor may have you wear a rigid back brace or cast for two to three months. Keeping the spine from moving can help ease pain and inflammation. Some patients who continue to have symptoms are given an *epidural steroid injection* (ESI). Steroids are powerful anti-inflammatories, meaning they reduce pain and swelling. In an ESI, medication is injected into the space around the lumbar nerve roots. This area is called the *epidural space*. Some doctors inject only a steroid. Most doctors, however, combine a steroid with a long-lasting numbing medication. Generally, an ESI is given only when other treatments aren't working. But ESIs are not always successful in relieving pain. If they do work, they may only provide temporary relief.

Patients occasionally work with a physical therapist. After evaluating your condition, your therapist can assign positions and exercises to ease your symptoms. Your therapist can design an exercise program to improve flexibility in your low back and hamstrings and to strengthen your back and abdominal muscles.

Surgery is used when the slip is severe and when symptoms are not relieved with non-surgical treatments. Symptoms that cause an abnormal walking pattern, changes in bowel or bladder function, or steady worsening in nerve function require surgery. The main types of surgery for spondylolisthesis include:

**Laminectomy** - When the vertebra slips forward, the nearby nerves that exit the spine can become pinched or irritated. In addition, the size of the spinal canal in the problem area shrinks, placing pressure on the nerves inside the canal. To fix this, the lamina of the bony ring is removed to ease pressure on the nerves. The procedure to remove the lamina and release pressure on the nerves is called laminectomy. When the operation is done for spondylolisthesis, it is normally combined with a fusion of the involved vertebrae (see below).

**Posterior Fusion with Instrumentation** - A spinal *fusion* is normally done immediately after laminectomy for spondylolisthesis. The fusion procedure is designed to fuse the two vertebrae into one bone and stop the slippage from worsening. The fusion is used to lock the vertebrae in place and stop movement between the vertebrae, easing mechanical

pain. When combined with laminectomy surgery (mentioned earlier), fusion helps relieve nerve compression. In this procedure, the surgeon lays small grafts of bone over the back of the problem vertebrae. Most surgeons also apply metal plates and screws (*instrumentation*) to prevent the two vertebrae from moving. This protects the graft so it can heal better and faster.

**Posterior Lumbar Interbody Fusion** - When fusion surgery is needed for mild spondylolisthesis (up to 50 percent slippage), *posterior lumbar interbody fusion* may be considered. In this procedure, the problem vertebrae are fused from the *anterior* (front) and *posterior* (back). Combining fusion of both portions of the spine gives a solid fusion. The surgeon works from the back of the spine and removes the disc between the problem vertebrae. Bone graft material is inserted from the back of the spine into the space between the two vertebrae where the disc was removed (the *interbody* space). The graft may be held in place with a special fusion cage that spreads and holds the vertebrae apart. Surgeons usually apply some form of instrumentation (described above) on the back of the vertebrae. In some cases, additional strips of bone graft are placed along the back surfaces of the vertebrae to be fused.

**X-Stop** – In limited cases, where the slippage is small, and there is no evidence of spondylolysis (where the lamina has become disconnected from the pedicles), an X-Stop might help. This is a small spacer placed between the spinous process bones. It keeps the spine from arching backwards at the treated level, which keeps the canal open. In the patient with mild to moderate symptoms that go away with sitting down or leaning forward, the X-Stop may be effective.